ORIGINAL ARTICLE

New Technique for Cryoneuroablation of the Proximal Greater Occipital Nerve

Agnes Stogicza, MD*; Andrea Trescot, MD†; David Rabago, MD‡

*Department of Anesthesiology and Pain Medicine, St Paul's Hospital, University of British Columbia, Vancouver, British Columbia, Canada; †Pain and Headache Center, Eagle River, Alaska, U.S.A.; ‡Department of Family Medicine, University of Wisconsin, Madison, Wisconsin, U.S.A.

■ **Abstract**

Study design: Description of a new technique.
Objectives: To describe a safe ultrasound (US)-guided cryoneuroablation technique of the proximal greater occipital nerve (GON).
Background: Cryoneuroablation is a treatment option for occipital neuralgia, providing more sustained relief when steroid injections fail. US can identify the proximal GON between the C2 spinous and C1 transverse process over the inferior oblique capitis muscle (IOCM), where the GON is clearly visualized. US-guided GON injections are often performed with an out-of-plane approach; however, that approach is difficult with cryoneuroablation, because the probe has no opening (prohibiting hydrodissection), and the size and dullness of the probe hinders easy manipulation.
Setting: University-based outpatient pain clinic.
Methods: We provide a description of the procedure based on experience in the authors' clinic. With the patient in the prone position, the US probe is placed parallel to the IOCM. The GON is seen on top of the IOCM; a midline 2-mm incision allows access to the bilateral GONs with a single skin entry. Using an in-plane approach, the cryo probe is advanced to the nerve in a medial-to-lateral direction, with constant US visualization, staying far away from the spinal cord and vertebral artery, which increases safety.
Conclusions: Based on anecdotal evidence from the authors' clinic, cryoneuroablation of the proximal GON can be performed safely at the level of the IOCM.
Limitations: The procedure described is based on anecdotal evidence from a small number of patients; however, the procedure is promising and formal study is warranted.
Lay Summary: Chronic headaches can develop after accidents or wear and tear from poor posture. They are challenging to treat, and steroid injections often fail to provide sustained relief. Once the occipital nerve is identified as a source of pain, it may be treated with cryoablation, which is freezing the nerve with a needle at the back of the head. ■

Key Words: cryoablation, cryoanalgesia, cryoneuroablation, occipital neuralgia, proximal occipital neuralgia, migraine, cephalgia, headache, GON

BACKGROUND

Occipital neuralgia is a difficult-to-treat pain condition, commonly observed with impaired posture and after flexion–extension injuries of the cervical spine. Patients typically complain of unilateral or bilateral headaches that originate at the upper cervical spine, with pain and tenderness at the back of the head that radiates to the top of the head, often referring pain to behind the eye. It can spread from one side to the other as the condition worsens and can lead to migraine-like headaches with photophobia, phonophobia, as well as nausea and vomiting. According to the International Headache

Address correspondence and reprint requests to: Agnes Stogicza, MD, Department of Anesthesiology and Pain Medicine, St Paul's Hospital, University of British Columbia, Kinizsi u.39. Budapest,1039, Hungary. E-mail: stogiagi@yahoo.com
Submitted: October 19, 2018; Revised January 31, 2019; Revision accepted: February 13, 2019
DOI. 10.1111/papr.12779

© 2019 World Institute of Pain, 1530-7085/18/$15.00

Society, the diagnosis is confirmed with diagnostic occipital nerve injection.[1] Possible etiologies of occipital neuralgia include irritation of the greater occipital nerve (GON) close to its origin at C1–C2 facets,[2] as well as entrapment of the GON by the deep or superficial cervical muscles through which it travels.

Cryoneuroablation (CNA) has been described for the GON,[3] but the location of this neurolysis has been at the nuchal ridge or the base of the skull, distal to the most proximal entrapment, and these have mostly been landmark guided. The GON at the nuchal ridge shows large anatomic variation and may be located anywhere between 0.5 and 7.5 cm from midline.[4,5] CT-guided CNA of the GON at the more proximal location was reported in 7 patients; however, the use of CT is less accessible and also leads to more radiation exposure.[6] The recent description of an ultrasound (US)-guided proximal GON injection technique[7] allowed the development of this more proximal CNA technique. We have used this technique to very good effect in our university-based pain clinic in patients who noted good but only temporary relief from proximal GON injections under US, and here, we provide a description of the procedure based on this experience. We include a brief description of the use of the procedure in the authors' clinic.

Anatomy

The GON arises from the posterior ramus of C2 that runs inferiorly between the arch of C1 and the lamina of C2 lateral to the lateral atlanto-axial (AA) joint, deep to the inferior oblique capitis muscle (IOCM). The GON then curves up over the IOCM, between the IOCM and the semispinalis capitis muscles (Figure 1). A branch from C3 may join at this point, as the nerve ascends up the neck and over the dorsal surface of the rectus capitis to pierce the semispinalis capitis muscle, deep to the trapezius muscle. The GON pierces through the aponeurosis of the trapezius muscle[8] (Figure 2), and branches run cephalad at the back of the head. Connections of the GON with the lesser and third occipital nerve, as well as variations in the GON branching at the occipital region and the variable relationship between the GON and occipital artery at the nuchal ridge, have been demonstrated,[9] and this may contribute to the lack of specificity seen with landmark-guided injections at the nuchal ridge. Furthermore, there is a high variability in the distance of the GON from the midline in the intermastoid line, as was shown by Loukas et al. (1.5 to 7.5 cm) and Becser et al. (from 0.5 to 3 cm).[4,5]

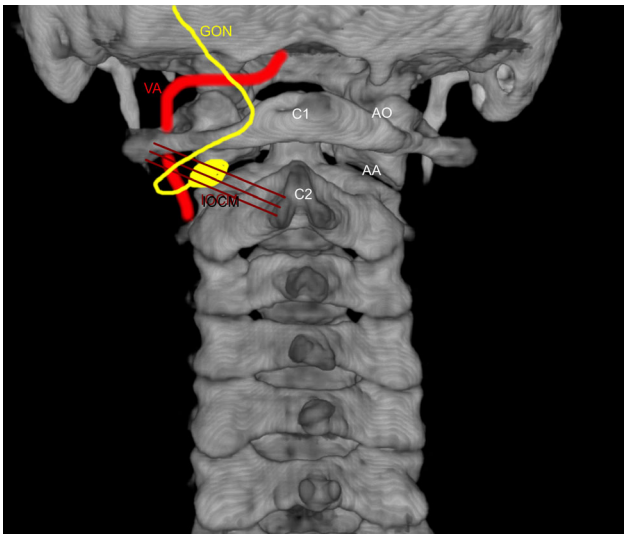

Figure 1. Diagram of the greater occipital nerve. AA joint, atlanto-axial joint; AO joint, atlanto-occipital joint; GON, greater occipital nerve; IOCM, inferior oblique capitis muscle; VA, vertebral artery. Image courtesy of Andrea Trescot, MD.

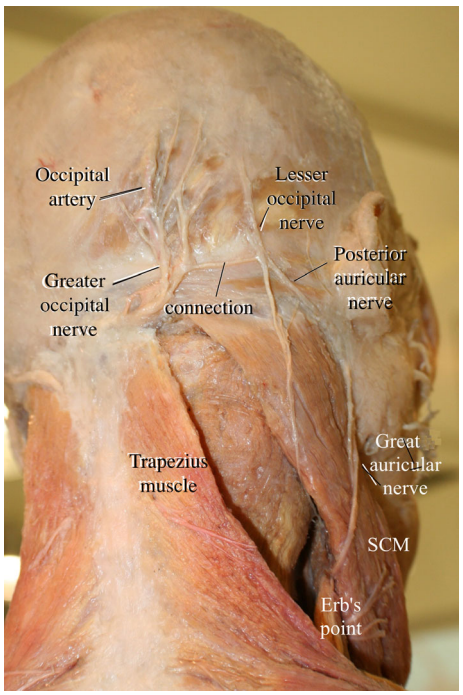

Figure 2. Dissection of the occipital region. A connection between the greater and lesser occipital nerve is visible. SCM, sternocleidomastoid muscle. Image courtesy of Dr. Hong-Jin Sui.

Treatment Options

There are a variety of minimally invasive treatments used for occipital neuralgia, including steroid injections, pulse radiofrequency (PRF), cryoneuroablation (CNA),

radiofrequency ablation (RFA), occipital stimulation, and C2 gangliotomy, all of which have been performed with some success.[2,3,10–12] Steroid injections, RFA, PRF, and CNA are often done at the nuchal ridge, just medial to the occipital artery. This "classical" approach, although relatively safe and easily performed, is not target specific, and usually requires larger amounts of local anesthetic. The injection might involve the other nerves in the vicinity (eg, the lesser and third occipital nerves), and therefore it loses its diagnostic value.[13] Greher et al.[7] described a more proximal US-guided injection technique between the C1 transverse and C2 spinous processes just above the IOCM, where the occipital nerve is clearly visible with US (see Methods). This latter technique allows a precise needle placement, along with a selective diagnostic block (recognizing that, because the third occipital nerve lies only a short distance away, it is often also anesthetized, even with small volumes),[13] and a precision ablative technique. Also, as the occipital nerve often splits to several branches before reaching the nuchal ridge,[14] this proximal technique allows capturing most of the branches, prior to the splitting of the nerve.

In this article, we report a US-guided CNA technique for unilateral or bilateral greater occipital neuralgia, performed at the proximal location.

Cryoneuroablation

CNA causes Wallerian degeneration due to the loss of continuity of the axon through a second-degree freeze. The endoneurium, perineurium, and epineurium, however, remain intact, which allows regeneration of the nerve later on.[15,16] As CNA is a reversible nerve-ablative technique without neuroma formation, it can be performed on any peripheral nerves, even larger myelinated nerves such as the occipital nerve. It creates a similar functional loss as local anesthetic; therefore, one must consider the consequences if including motor nerves, though any motor deficit would be expected to resolve.[17] Complications are rare (<10%), but include temporary neuritis, allodynia, and new neuropathic pain as a potential result of a direct nerve lesion.[3]

US has recently been used for more precise peripheral nerve injections; CNA has been used with US guidance for several other peripheral nerves.[18,19]

METHODS

Several steps are required for safe visualization and CNA of the proximal GON.

GON Identification

The patient is placed in a prone position with a face ring, pillow under the chest, with the neck in as maximally flexed position as patient comfort allows. A general preprocedure scan is recommended for safety. We used a Sonosite X-Porte US (FUJIFILM SonoSite, Inc., Bothell, WA, USA) machine with a standard linear probe (15 to 6 MHz); however, for patients with a thick neck, and those who have had previous surgeries, a curvilinear probe might facilitate visualization (Figure 5).

The US probe is placed horizontally over the C2 spinous process, which is a bifid spinous process, and the first palpable bony structure in the midline, just caudad of the occiput (Figure 3). Of note, scanning cephalad will show only a deep, rounded arch of C1 and no more spinous processes. Be aware that C2 and C3 can look very similar, and thus, the cephalad scanning is important.

The lamina leading up to the C2 spinous process is visualized, with the IOCM noted immediately over the bone. Sliding somewhat laterally and rotating the probe

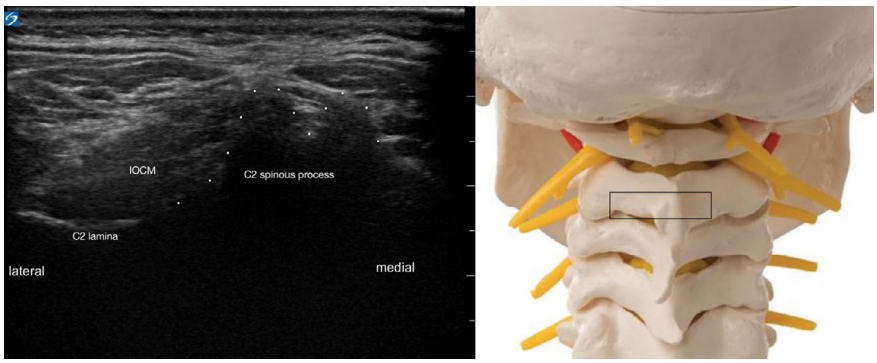

Figure 3. Ultrasound image, horizontal probe placement at C2 level. IOCM, inferior oblique capitis muscle. Image courtesy of Agnes Stogicza, MD.

towards the C1 transverse process then adding a 5- to 10-degree caudad tilt usually allows a view of the IOCM, the slope of C2 lamina, the shadow of the C1 transverse process, and the greater occipital nerve (Figure 4). Keeping the IOCM visualized in its full width, clearly showing fibers in a longitudinal view, helps to get the best image. The GON is usually seen in short axis as a round hypoechoic structure immediately on top of the IOCM, at the junction of the medial one third and lateral two thirds of the length of the IOCM (Figure 4).

Sliding the probe in a cephalad direction without any angle change allows tracking of the nerve moving medially towards the spinous process, while sliding the probe caudally, again without any angle change, will allow visualization of the nerve moving slightly laterally before it dips down under the IOCM. This visualization confirms the structure as the GON. The corresponding image using the curvilinear probe can be seen in Figure 5.

Diagnostic Injection

All patients should undergo diagnostic injections by the same proceduralist who will be performing the CNA if the diagnostic block proved successful. This is important, as the diagnostic injection also functions as a prescan, to assure that the more involved CNA with a larger gauge needle will be technically feasible.

The diagnostic injection is performed under US guidance with 1 mL of lidocaine 2%, using a 25-gauge needle and an out-of-plane approach, which allows a shorter needle track to decrease patient discomfort (Figure 6). Success of the injection is defined by numbness at the back of the head and at least 80% resolution of a headache within minutes of the procedure, lasting a few hours. With this minimal amount of local anesthetic, the length of numbness is usually only 1 to 2 hours; however, the pain relief is often observed to last longer, especially if steroids are included in the injection. Saving an image of the diagnostic procedure will facilitate target identification during cryoneuroablation.

Cryoneuroablation of the GON

If the diagnostic injection was temporarily successful, the patient was then scheduled for CNA of the affected nerves. Moderate sedation is often used to decrease patient discomfort; however, it is advised that the patient be awake and cooperating throughout the whole procedure to increase procedural safety.

Our patients signed consents prior to treatment. Institutional review board approval was not sought, as patient care met the Declaration of Helsinki guidelines, in particular section 32, which pertains to new therapeutic measures and the recording of new information. We used the Wallach WA1000B Cryosurgical System (Epimed International, Dallas, TX, USA), which utilizes compressed N_2O and trochar-tipped 14-gauge cryo probes.

Differences between targeting the GON with a sharp 25-gauge needle and a larger (usually 14- to 18-gauge) cryo probe:

1. Cryo probes are dull compared to any 22- or 25-gauge sharp hypodermic needle, which means an introducer is usually required.
2. Navigation of the probe within the tissues is more difficult and requires much control to prevent the probe from accidentally sliding too deep.
3. When the cryo probe (14- to 18-gauge) is well visualized with US, it creates a large barrier to the echo, and the structures beneath it are visualized very poorly.

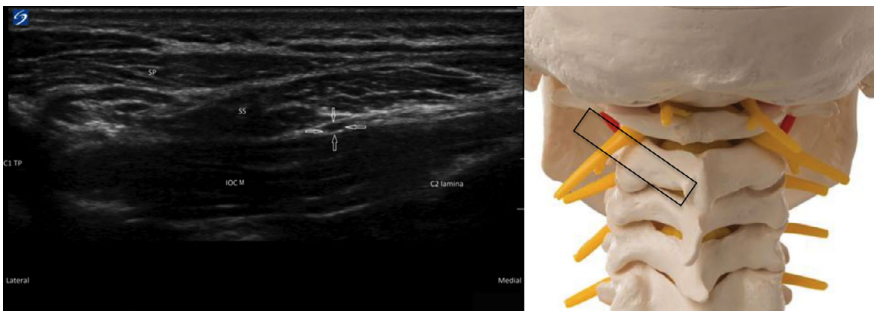

Figure 4. Ultrasound image of the suboccipital structures. Arrows point to the greater occipital nerve. C1TP, C1 transverse process; IOCM, inferior oblique capitis muscle; SP, splenius muscle; SS, semispinalis muscle. Image courtesy of Agnes Stogicza, MD.

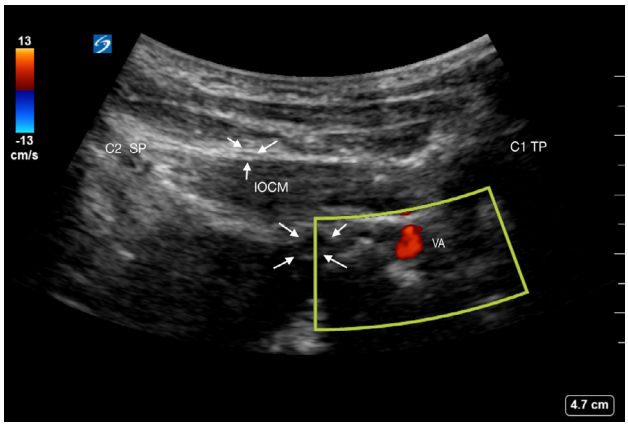

Figure 5. Overview of the suboccipital area with a curvilinear probe. Three arrows mark the greater occipital nerve at the junction of the medial one third and lateral two thirds of the length of the inferior oblique capitis muscle (IOCM). Four arrows mark the C2 DRG. C1 SP, C1 spinous process; C2 SP, C2 spinous process; VA, vertebral artery. Image courtesy of Agnes Stogicza, MD.

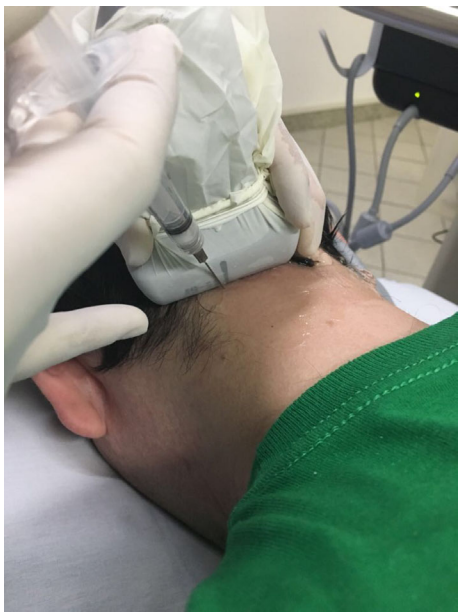

Figure 6. Ultrasound probe placement for the proximal occipital nerve diagnostic injection, out-of-plane approach. The needle is almost parallel to the beam, entering the skin immediately next to the caudad side of ultrasound probe. Image courtesy of Agnes Stogicza, MD.

4. As cryo probes are closed systems within which compressed gas circulates, there is no opening; therefore, hydrodissection to identify the needle tip is not possible.
5. Only an in-plane approach is advised, which ensures that the cryo probe tip is perfectly localized on the nerve, and also allows safe positioning, bearing in mind the high-risk structures in the vicinity. Not visualizing the probe tip at this location while moving the probe is an absolute risk and therefore must be avoided.
6. The probe entry site must be precisely picked to facilitate clear visualization of both the target and the cryo probe in the same view.

In spite of these difficulties, the procedure can be safely performed with adequate planning.

Safety Considerations

1. The epidural space, intrathecal space, and spinal cord are only centimeters away from the target and widely exposed between C1 and C2 vertebrae, especially when the neck is flexed.
2. The vertebral artery is just lateral to the C2 vertebra and traverses laterally towards the foramen transversarium of C1.
3. The C2 dorsal root ganglion and exiting nerve root of C1 and C2 are also in the vicinity of the target.

Cryoneuroablation Procedure Description

Patient positioning and nerve identification occur as described above. After sterile preparation and draping, 2 to 3 mL of local anesthetic is infiltrated in the midline cutaneous and subcutaneous tissues at the planned cryo probe entry point and in the direction of the GON via a 27- or 30-gauge needle. After a small, 2-mm skin incision is created, a 12-gauge IV catheter is used as an introducer and is placed through the subcutaneous tissues, the trapezius muscles, and the semispinalis capitis muscles, towards the GON. The catheter tip is placed close to the occipital nerve on the surface of the IOCM and the stylet removed. The cryo probe is then advanced through the catheter (Figure 7) and advanced to the GON under US guidance. Even without any electric stimulation, the patient often confirms that the placement of the probe provoked a paresthesia at the back of the head. Sensory stimulation (50 Hz) at progressively lower voltage (from 1 Volt to 0.3 Volt) can aid to accurately position the probe directly on the nerve if visualization is not sufficiently clear.

Three 2-minute CNA cycles are then performed at −70°C. The ice-ball appears as a hyperechoic round structure at the tip of the cryo probe and prevents the echo from spreading beyond the probe (Figure 8). As

Figure 7. Cryo probe placement from midline to lateral, in-plane approach. The ultrasound probe used for visualization has been removed for better view of the area. Image courtesy of Agnes Stogicza, MD.

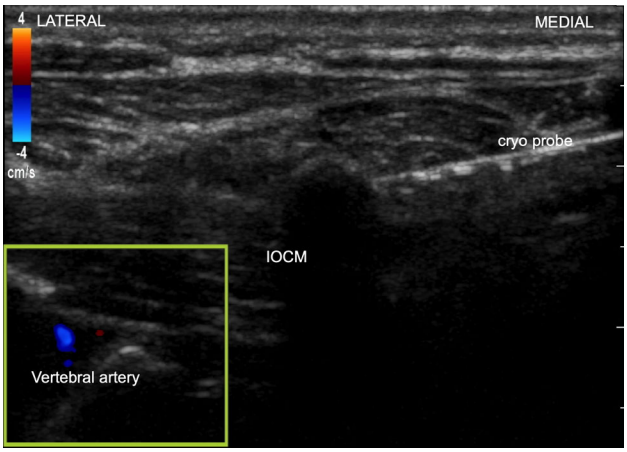

Figure 9. Ultrasound image of the cryo probe and ice ball, with color Doppler view to demonstrate the vertebral artery. IOCM, inferior oblique capitis muscle. Image courtesy of Agnes Stogicza, MD.

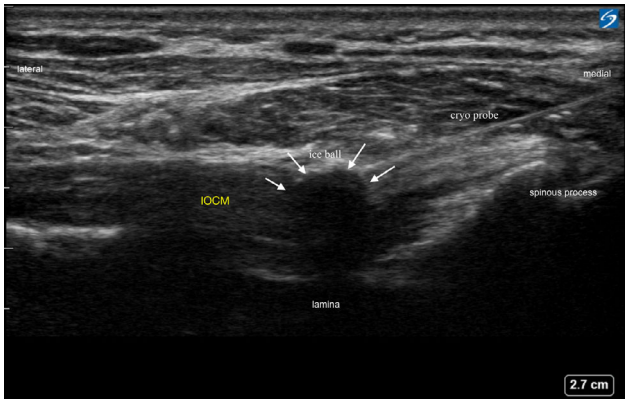

Figure 8. Ultrasound image of the cryo probe and ice ball. IOCM, inferior oblique capitis muscle. Image courtesy of Agnes Stogicza, MD.

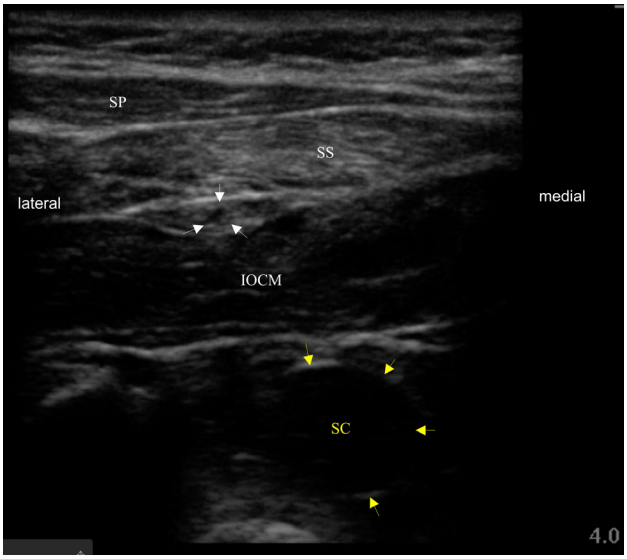

Figure 10. Ultrasound image of the proximal suboccipital structures. White arrows point to the greater occipital nerve. IOCM, inferior oblique capitis muscle; SP, splenius muscle; SS, semispinalis muscle; yellow arrows mark the dura, which contains the spinal cord (SC). Image courtesy of Agnes Stogicza, MD.

described above, the nerve can be tracked by US back and forth in a cephalo-caudad direction, which allows confirmation that the ice-ball has incorporated the GON, by visualizing the "nerve–ice ball–nerve" sequence. The vertebral artery is in the trajectory of the needle; however, the artery is beneath the IOCM, far lateral to our target, and usually well visualized by 2-dimensional and color Doppler mode, so it can be easily avoided if US is used appropriately to identify anatomy (Figure 9). In patients with lower body mass index, it is also easy to visualize the spinal cord just beneath the IOCM, which again is helpful to understand risks and avoid them (Figure 10).

Utilizing a medial to lateral in-plane approach has multiple benefits:

1. Using an in-plane approach, the cryo probe is pointing from medial to lateral, which keeps the spinal cord safe, away from the needle trajectory.
2. One skin incision allows the approach to both sides.

Authors' Experience

With the above-described technique, we have performed this procedure more than 50 times, treating both

unilateral and bilateral occipital neuralgia. There have been no major complications. Minor complications were rare, consisting only of post-procedure soreness, which resolved spontaneously in 1 to 3 weeks.

DISCUSSION

GON neuralgia or entrapment and pathology can be caused by trauma, fibrositis, myositis, fracture of the atlas, compression of the C2 nerve root, C1–2 arthrosis syndrome and atlantoaxial lateral mass osteoarthritis,[20] cervical myelitis,[21,22] cervical cord tumor,[22,23] Chiari malformation, giant cell arteritis, neurosyphilis, and postoperatively after acoustic neuroma resection.[24] It is a common cause of headaches, and, because of the close association of the nerve and artery, it can present with unilateral throbbing pain, associated with nausea, vomiting, and emesis, meeting the International Headache Society criteria for migraine headaches. GON injections have been used for cervicogenic,[25] cluster-type,[26] and post-dural puncture headaches.[27]

Marked location variability and multiple branching of the GON can exist at the distal, classical block site, which is the reason that relatively high volumes of local anesthetic are used for blind (landmark-guided) injections at this location.[8] This often results in nonselective blockade of other nerves, including branches of the lesser and third occipital nerve, as well as the great auricular nerve.

There are several advantages to using US for GON injections. It allows for the most proximal injection of the GON, just posterior to the IOCM, which can be easily visualized under US. In addition, positioning the US probe so that the full thickness of the IOCM overlies the bony shadow of the C2 lamina confers improved safety when performing this technique, eliminating any possibility of inadvertent spinal cord or vertebral artery puncture. Under no circumstances should this new approach be performed without direct US guidance.

US has been used successfully to locate and localize other nerves for CNA.[18] This new, proximal US-guided CNA approach has several advantages compared to the classical, more distal one. At the C2 level, which is below the hairline, skin disinfection is easier, and shaving is normally not necessary. Here, the nerve is deeper, lying between tissues that have a distinct sonographic appearance, without bony artifacts and not in close proximity to an artery. At this level, selective cryoanalgesic techniques can be performed without the potential danger of occipital artery damage. Proximal blockade of nerves often provides better results than the distal approaches, especially in occipital neuralgia, where nerve entrapment may be proximal. Gille and colleagues[28] showed that neurolysis of the GON and sectioning of the IOCM at C2 was highly successful when performed in selected patients.

CONCLUSION

GON is a common cause of headaches, and treatment options have been limited. Approaches to the occipital nerve now include a proximal injection under US. Here, we have presented a new cryoneuroablation technique of the proximal greater occipital nerve. It allows for an advanced, safe treatment option of treating occipital neuralgia without the side effects of repeated steroid use.

ACKNOWLEDGEMENTS

The Plastinated Human specimen shown in this article was produced by Prof. Dr. Hong-Jin Sui, Director of Anatomy of the Dalian Medical University, China, and Dalian Hoffen Biotechnique Co. Ltd, China, and is used here with their permission. The authors wish to thank Dr. Sui and Dalian Hoffen Biotechnique Co. Ltd. for permission to use the photograph of this specimen.

FUNDING

The authors declare that no outside funding or editorial support was obtained for this article.

CONFLICTS OF INTEREST

The authors have no conflicts of interest to declare.

REFERENCES

1. Olesen J, Bes A, Kunkel R, et al. The International Classification of Headache Disorders, 3rd edition (beta version). *Cephalalgia*. 2013;33:629–808.

2. Stechison MT, Mullin BB. Surgical treatment of greater occipital neuralgia: an appraisal of strategies. *Acta Neurochir (Wien)*. 1994;131:236–240.

3. Kim CH, Hu W, Gao J, Dragan K, Whealton T, Julian C. Cryoablation for the treatment of occipital neuralgia. *Pain Physician*. 2015;18:E363–E368.

4. Loukas M, El-Sedfy A, Tubbs RS, Louis RG Jr, ChT W, Curry B. Identification of greater occipital nerve landmarks for the treatment of occipital neuralgia. *Folia Morphol (Warsz)*. 2006;65:337–342.

5. Becser N, Bovim G, Sjaastad O. Extracranial nerves in the posterior part of the head. Anatomic variations and their possible clinical significance. *Spine (Phila Pa 1976)*. 1998;23:1435–1441.

6. Kastler A, Attyé A, Maindet C, et al. Greater occipital nerve cryoneurolysis in the management of intractable occipital neuralgia. *J Neuroradiol*. 2017;45:386–390.

7. Greher M, Moriggl B, Curatolo M, Kirchmair L, Eichenberger U. Sonographic visualization and ultrasound-guided blockade of the greater occipital nerve: a comparison of two selective techniques confirmed by anatomical dissection. *Br J Anaesth*. 2010;104:637–642.

8. Natsis K, Baraliakos X, Appell HJ, Tsikaras P, Gigis I, Koebke J. The course of the greater occipital nerve in the suboccipital region: a proposal for setting landmarks for local anesthesia in patients with occipital neuralgia. *Clin Anat*. 2006;19:332–336.

9. Junewicz A, Katira K, Guyuron B. Intraoperative anatomical variations during greater occipital nerve decompression. *J Plast Reconstr Aesthet Surg*. 2013;66:1340–1345.

10. Vanderhoek MD, Hoang HT, Goff B. Ultrasound-guided greater occipital nerve blocks and pulsed radiofrequency ablation for diagnosis and treatment of occipital neuralgia. *Anesth Pain Med*. 2013;3:256–259.

11. Vanelderen P, Rouwette T, De Vooght P, et al. *P*ulsed radiofrequency for the treatment of occipital neuralgia: a prospective study with 6 months of follow-up. *Reg Anesth Pain Med*. 2010;35:148–151.

12. Cohen SP, Peterlin BL, Fulton L, et al. Randomized, double-blind, comparative-effectiveness study comparing pulsed radiofrequency to steroid injections for occipital neuralgia or migraine with occipital nerve tenderness. *Pain*. 2015;156:2585–2594.

13. Silva K, Wahezi S, Downie S, Emam M, Lederman A. Cervical third occipital nerve blocks concomitantly affect the greater occipital nerve: cadaveric study. Presented at the NYNJSIPP (New York and New Jersey Society of Interventional Pain Physicians) annual meeting; 2014; Jersey City, NJ.

14. Tubbs RS, Salter EG, Wellons JC, Blount JP, Oakes WJ. Landmarks for the identification of the cutaneous nerves of the occiput and nuchal regions. *Clin Anat*. 2007;20:235–238.

15. Zhou L, Kambin P, Casey KF, et al. Mechanism research of cryoanalgesia. *Neurol Res*. 1995;17:307–311.

16. Sunderland S. *Nerves and Nerve Injuries*. Edinburgh & London: Livingston; 1968.

17. Hsu M, Stevenson FF. Wallerian degeneration and recovery of motor nerves after multiple focused cold therapies. *Muscle Nerve*. 2015;51:268–275.

18. Friedman T, Richman D, Adler R. Sonographically guided cryoneurolysis: preliminary experience and clinical outcomes. *J Ultrasound Med*. 2012;31:2025–2034.

19. Rhame EE, Debonet AF, Simopoulos TT. Ultrasonographic guidance and characterization of cryoanalgesic lesions in treating a case of refractory sural neuroma. *Case Rep Anesthesiol*. 2011;2011:691478.

20. Aprill C, Axinn MJ, Bogduk N. Occipital headaches stemming from the lateral atlanto-axial (C1-2) joint. *Cephalalgia*. 2002;22:15–22.

21. Goicochea MT, Romero C, Leston JA. Occipital neuralgia with cervical myelitis. *Cephalalgia*. 2008;28:567–568.

22. Lee SY, Jang DI, Noh C, Ko YK. Successful treatment of occipital radiating headache using pulsed radiofrequency therapy. *J Korean Neurosurg Soc*. 2015;58:89–92.

23. Baer-Henney S, Tatagiba M, Samii M. Osteochondroma of the cervical spine causing occipital nerve neuralgia. Case report. *Neurol Res*. 2001;23:777–779.

24. Ducic I, Felder JM 3rd, Endara M. Postoperative headache following acoustic neuroma resection: occipital nerve injuries are associated with a treatable occipital neuralgia. *Headache*. 2012;52:1136–1145.

25. Inan N, Ceyhan A, Inan L, Kavaklioglu O, Alptekin A, Unal N. C2/C3 nerve blocks and greater occipital nerve block in cervicogenic headache treatment. *Funct Neurol*. 2001;16:239–243.

26. Peres MF, Stiles MA, Siow HC, Rozen TD, Young WB, Silberstein SD. Greater occipital nerve blockade for cluster headache. *Cephalalgia*. 2002;22:520–522.

27. Akin Takmaz S, Ünal Kantekin C, Kaymak Ç, Başar H. Treatment of post-dural puncture headache with bilateral greater occipital nerve block. *Headache*. 2010;50:869–872.

28. Gille O, Lavignolle B, Vital JM. Surgical treatment of greater occipital neuralgia by neurolysis of the greater occipital nerve and sectioning of the inferior oblique muscle. *Spine (Phila Pa 1976)*. 2004;29:828–832.